

RESEARCH

Open Access



# Longitudinal assessment of interstitial lung abnormalities on CT in patients with COPD using artificial intelligence-based segmentation: a prospective observational study

Yusuke Shiraishi<sup>1</sup>, Naoya Tanabe<sup>1,9\*</sup>, Ryo Sakamoto<sup>2</sup>, Tomoki Maetani<sup>1</sup>, Shizuo Kaji<sup>3</sup>, Hiroshi Shima<sup>1</sup>, Satoru Terada<sup>1,4</sup>, Kunihiro Terada<sup>4</sup>, Kohei Ikezoe<sup>1</sup>, Kiminobu Tanizawa<sup>1</sup>, Tsuyoshi Oguma<sup>1,5</sup>, Tomohiro Handa<sup>1,6</sup>, Susumu Sato<sup>1,7</sup>, Shigeo Muro<sup>8</sup> and Toyohiro Hirai<sup>1</sup>

## Abstract

**Background** Interstitial lung abnormalities (ILAs) on CT may affect the clinical outcomes in patients with chronic obstructive pulmonary disease (COPD), but their quantification remains unestablished. This study examined whether artificial intelligence (AI)-based segmentation could be applied to identify ILAs using two COPD cohorts.

**Methods** ILAs were diagnosed visually based on the Fleischner Society definition. Using an AI-based method, ground-glass opacities, reticulations, and honeycombing were segmented, and their volumes were summed to obtain the percentage ratio of interstitial lung disease-associated volume to total lung volume (ILDvol%). The optimal ILDvol% threshold for ILA detection was determined in cross-sectional data of the discovery and validation cohorts. The 5-year longitudinal changes in ILDvol% were calculated in discovery cohort patients who underwent baseline and follow-up CT scans.

**Results** ILAs were found in 32 (14%) and 15 (10%) patients with COPD in the discovery ( $n = 234$ ) and validation ( $n = 153$ ) cohorts, respectively. ILDvol% was higher in patients with ILAs than in those without ILA in both cohorts. The optimal ILDvol% threshold in the discovery cohort was 1.203%, and good sensitivity and specificity (93.3% and 76.3%) were confirmed in the validation cohort. 124 patients took follow-up CT scan during  $5 \pm 1$  years. 8 out of 124 patients (7%) developed ILAs. In a multivariable model, an increase in ILDvol% was associated with ILA development after adjusting for age, sex, BMI, and smoking exposure.

**Conclusion** AI-based CT quantification of ILDvol% may be a reproducible method for identifying and monitoring ILAs in patients with COPD.

**Keywords** Artificial intelligence, CT, COPD, Interstitial lung abnormality

\*Correspondence:

Naoya Tanabe  
ntana@kuhp.kyoto-u.ac.jp

Full list of author information is available at the end of the article



© The Author(s) 2024. **Open Access** This article is licensed under a Creative Commons Attribution 4.0 International License, which permits use, sharing, adaptation, distribution and reproduction in any medium or format, as long as you give appropriate credit to the original author(s) and the source, provide a link to the Creative Commons licence, and indicate if changes were made. The images or other third party material in this article are included in the article's Creative Commons licence, unless indicated otherwise in a credit line to the material. If material is not included in the article's Creative Commons licence and your intended use is not permitted by statutory regulation or exceeds the permitted use, you will need to obtain permission directly from the copyright holder. To view a copy of this licence, visit <http://creativecommons.org/licenses/by/4.0/>. The Creative Commons Public Domain Dedication waiver (<http://creativecommons.org/publicdomain/zero/1.0/>) applies to the data made available in this article, unless otherwise stated in a credit line to the data.

## Background

Smoking and aging cause a variety of chronic respiratory diseases, such as chronic obstructive pulmonary disease (COPD) and interstitial lung disease (ILD). COPD is pathologically characterized by alveolar destruction, known as emphysema, and small airway disease, leading to persistent airflow limitations and respiratory symptoms [1], while ILD is characterized by inflammation and fibrotic changes in the lung parenchyma [2]. Although the underlying pathophysiology of ILD is different from that of COPD, the coexistence of emphysema and ILD is common and known as combined pulmonary fibrosis and emphysema (CPFE) [3, 4]. This condition is associated with a high incidence of lung cancer and pulmonary hypertension, leading to a poor prognosis [3, 5], but its pathogenesis remains unknown.

In contrast with histological analyses in which coexistence of emphysema and fibrosis is easily observed [6], fibrotic changes in emphysematous regions are subtle and cannot be resolved on high-resolution computed tomography (HRCT). However, interstitial lung abnormalities (ILAs) can be incidentally identified on CT in a subgroup of patients with COPD [7]. The presence of ILAs in patients with COPD has a negative impact on clinical outcomes [8, 9], and indeed, it is possible that ILAs are a precursor of CPFE. Therefore, the early detection of ILAs and assessment of their progression, particularly using an objective and reproducible quantification method, are crucial.

As the need for computer-aided CT analysis for ILD has increased, various methods of quantitative CT analysis have emerged, such as densitometry, texture analysis, and artificial intelligence (AI)-based methods [10]. AI-based image analysis has advantages in terms of high reliability and reproducibility over other methods. Furthermore, indices derived from AI-based image analysis have been associated with pulmonary function decline, exacerbation, and prognosis in ILD [11–13]. Artificial intelligence based quantitative CT image analysis software (AIQCT) is an AI-based image analysis software that can automatically classify chest CT images into normal lung, ground-glass opacities (GGOs), reticulations, consolidations, honeycombing, nodules, hyperlucencies, interlobular septum, bronchi, and vessels [14]. Both normal lung regions and the bronchus volume quantified using AIQCT have been associated with a poor prognosis in patients with idiopathic pulmonary fibrosis (IPF) [14]. However, the utility and applicability of AIQCT for quantifying ILAs in patients with COPD remains unclear.

Therefore, this study aimed to test the utility of AIQCT in evaluating the presence of ILAs in two independent COPD patient cohorts as well as ILA development using the longitudinal data from one of the cohorts.

Furthermore, the study explored abnormal CT patterns associated with the emergence of ILAs.

## Methods

### Study population and longitudinal analysis

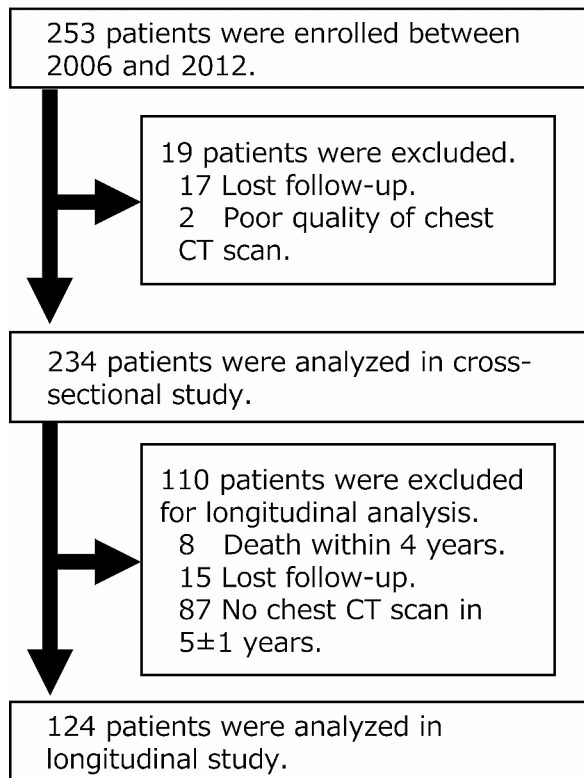
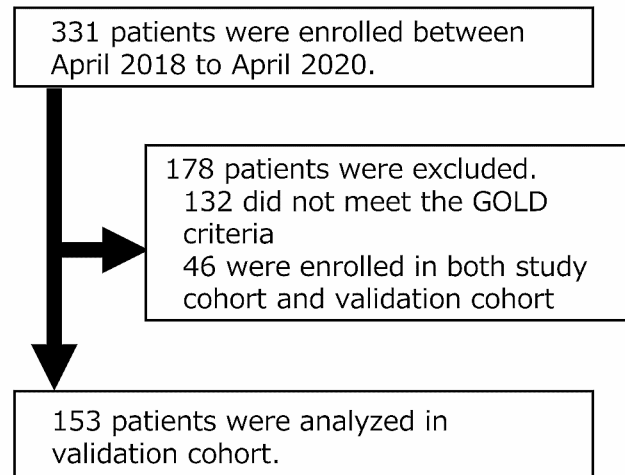
This is a retrospective analysis of two prospective observational cohorts of patients with COPD [15–18]. The discovery cohort included subjects who were older than 40 years, had a smoking exposure of more than 10 pack-years and were diagnosed with COPD according to the GOLD guidelines (forced expiratory volume in 1 s (FEV<sub>1</sub>)/forced vital capacity (FVC) less than 0.7 with respiratory symptoms) at Kyoto university hospital in 2006 to 2012. The exclusion criteria were (1) a diagnosis of ILD, (2) a prior history of lobectomy, and (3) inadequate CT images for quantitative analysis due to abnormal shadows such as pleural effusion, pneumonia, or poor quality. In addition to cross-sectional analysis, longitudinal analysis was performed on those who underwent chest CT scans within  $5 \pm 1$  years from baseline (shown in Fig. 1). The validation of the thresholds of AIQCT indices for detecting ILA was performed using an independent dataset from another cohort [18]. The validation cohort was a prospective observational cohort from Kyoto university hospital and a respiratory clinic (Terada Clinic), consisting of smokers aged  $\geq 40$  years with a history of  $\geq 10$  pack-years between April 2018 and April 2020. The details of the validation cohort are described in the additional file 1.

### CT acquisition and visual assessment of ILAs

In the discovery cohort, all chest CT scans were acquired at full inspiration using an Aquilion 64 (sharp kernels, 0.5 mm slice thickness, 120 kVp, and autoexposure control; Canon Medical Systems, Otawara, Japan). In the validation cohort, all chest CT scans were also acquired using an Aquilion Precision scanner or an Aquilion lightning scanner (sharp kernels, 1.0 mm slice thickness, 120 kVp, and autoexposure control; Canon Medical Systems, Otawara, Japan). Among one chest radiologist with 16 years' experience and two CT-experienced pulmonologists with  $\geq 8$  years' experience, two visually assessed ILAs in chest CT images according to the Fleischner Society statement [7]. Any cases of discordance were settled by a chest radiologist or consultation between the two raters. The patients' clinical information was blinded, and the baseline and follow-up images were not compared when assessing the follow-up CT scans.

### Quantitative CT analysis using AIQCT

Quantitative analysis of the chest CT scans was performed using AI-based image analysis software named AIQCT, which was originally developed in collaboration with FUJIFILM Corporation to quantify parenchymal and airway abnormalities in IPF [14]. AIQCT uses a

**(a) Discovery cohort****(b) Validation cohort****Fig. 1** Patient flow chartLegend: (Fig. 1. **a**) Discovery cohort, (Fig. 1. **b**) Validation cohort

network architecture based on U-Net and automatically classifies structures on chest CT images into the following groups: normal lung, ground-glass opacities (GGOs), reticulations, consolidations, honeycombing, nodules, hyperlucencies, interlobular septum, bronchi, and vessels. According to a previous report [12], interstitial lung disease volume (ILDvol) was defined as the combined volume of honeycombing, reticulations, and GGOs. The absolute ILDvol and the percentage of ILDvol to total lung volume (ILDvol%) were analyzed in this study.

**Statistical analysis**

Data are presented as the mean±standard deviation (SD) unless otherwise indicated. The kappa coefficient was calculated to assess interrater reliability in the visual assessment of ILA [19]. Receiver operating characteristic (ROC) curve analyses and the Youden index were used to obtain the optimal threshold of ILDvol% in each lung volume fraction for detecting ILA. The areas under the ROC curves (AUCs) were compared using the DeLong test, and p values were corrected by the Bonferroni method. To test whether the diagnostic performance could be improved, sensitivity analysis was done in which the lung volume was equally divided into three or ten parts along

the craniocaudal axis, and the highest ILDvol in each fraction was used in ROC curve analysis. Longitudinal changes in AIQCT indices were compared between subjects with new ILAs and those consistently without ILAs using the t test. Furthermore, adjusted mean differences in AIQCT indices were calculated, including age, sex, BMI, smoking status, and cumulative smoking exposure as covariates. Statistical analyses were performed using R statistical software version 4.3.1.

**Results****Study population and quantified CT features**

Among 234 subjects, 32 (14%) had ILAs in the discovery cohort, and 15 out of 153 patients (9.8%) had ILAs in the validation cohort (Table 1). Interrater reliability for the visual assessment of ILAs was fair to moderate (kappa coefficient=0.323–0.525, agreement=81–88%). Compared to subjects without ILAs, those with ILAs were older and showed milder airflow limitation and a deteriorated diffusion capacity (Table 2). Table 2 also shows the AI-based quantification of CT features. The subjects with ILAs had higher incidences of honeycombing, reticulations, and GGOs than those without ILAs. Furthermore, nodule and bronchi volumes were greater in those with

**Table 1** Patient characteristics in the two cohorts

	Discovery cohort		Validation cohort	
n	234		153	
Age, y	69.9	± 8.2	71.9	± 8.3
Sex, male	215	(91.9%)	142	(92.8%)
BMI, kg/m <sup>2</sup>	22.0	± 2.9	23.1	± 3.8
Pack-years	65.3	± 34.4	58.9	± 30.0
Smoking status, past	177	(75.6%)	111	(72.5%)
mMRC, ≥2	58	(24.8%)	37	(24.2%)
FVC, L	3.22	± 0.76	3.04	± 0.92
% predicted	93.2	± 16.7	87.4	± 21.9
FEV <sub>1</sub> , L	1.62	± 0.62	1.66	± 0.68
% predicted	60.4	± 19.6	62.4	± 23.1
FEV <sub>1</sub> /FVC, %	49.8	± 13.0	54.0	± 12.0
Visual finding of ILAs	32	(13.7%)	15	(9.8%)

Data are the mean ± standard deviation or the number of patients with percentage in parentheses. BMI body mass index; mMRC modified British Medical Research Council Dyspnea scale; FVC forced vital capacity; FEV<sub>1</sub>, forced expiratory volume in 1 s; ILA interstitial lung abnormality

**Table 2** Clinical and radiological comparisons between patients with and without ILA in the discovery cohort

	No ILA		ILA		P value
n	202		32		
Age, y	69.4	± 8.1	73.1	± 8.0	0.016
Sex, male	185	(91.6)	30	(93.8)	0.945
BMI, kg/m <sup>2</sup>	21.9	± 2.8	22.7	± 3.4	0.155
Pack-years	64.5	± 34.7	70.8	± 32.0	0.338
Smoking status, past	150	(74.3)	27	(84.4)	0.309
mMRC, ≥2	47	(23.3)	11	(34.4)	0.258
FVC, L	3.22	± 0.77	3.18	± 0.72	0.77
% predicted	93.0	± 16.8	94.5	± 16.0	0.63
FEV <sub>1</sub> , L	1.59	± 0.62	1.80	± 0.56	0.065
% predicted	59.0	± 19.5	69.6	± 17.6	0.004
FEV <sub>1</sub> /FVC, %	48.8	± 13.0	56.3	± 10.7	0.002
D <sub>lCO</sub> , mL/min/mmHg	13.2	± 5.2	11.1	± 4.5	0.03
% predicted	60.1	± 21.8	52.1	± 20.1	0.054
Normal lungs, mL	4175	± 997	3488	± 876	< 0.001
ILD volume, mL	51.1	± 37.2	114.1	± 76.6	< 0.001
Ground-glass opacities, mL	43	± 32	66	± 66	0.001
Reticulations, mL	7.0	± 8.5	37.6	± 30.0	< 0.001
Consolidations, mL	7.7	± 3.9	8.8	± 3.4	0.141
Honeycombing, mL	1.0	± 1.7	10.0	± 18.9	< 0.001
Nodules, mL	5.7	± 4.9	11.7	± 9.6	< 0.001
Hyperlucencies, mL	821	± 1046	870	± 1058	0.806
Bronchi, mL	76.7	± 19.8	89.7	± 17.3	0.001
Vessels, mL	210	± 54	198	± 57	0.246

Data are the mean ± standard deviation or the number of patients with the percentage in parentheses. ILA interstitial lung abnormality; BMI body mass index; mMRC modified British Medical Research Council Dyspnea scale; FVC forced vital capacity; FEV<sub>1</sub>, forced expiratory volume in 1 s; DLCO diffusing capacity of the lung for carbon monoxide; ILD interstitial lung disease

ILAs than those without ILAs. The clinical and radiological characteristics of the validation cohort are described in Table S1. Representative images of the AIQCT analysis are shown in Fig. 2.

#### Diagnostic performance of AIQCT indices

By using ROC curve analysis, the optimal threshold of ILDvol% on whole lung for identifying ILAs was determined. As shown in Figure S1, the optimal threshold of ILDvol% on whole lung was 1.203%, and the area under the ROC curve was 0.863, with 87.5% sensitivity and 77.2% specificity. In sensitivity analysis using ILDvol% within a third or tenth of the whole lung volume, the sensitivity and specificity were also high, but the diagnostic performance was not improved (shown in Fig. S1). When the optimal threshold of ILDvol% on whole lung was applied to the validation cohort, the diagnostic performance was good (sensitivity was 99.3% and specificity was 76.3%).

#### Longitudinal changes in the visual assessment of ILAs and AIQCT indices

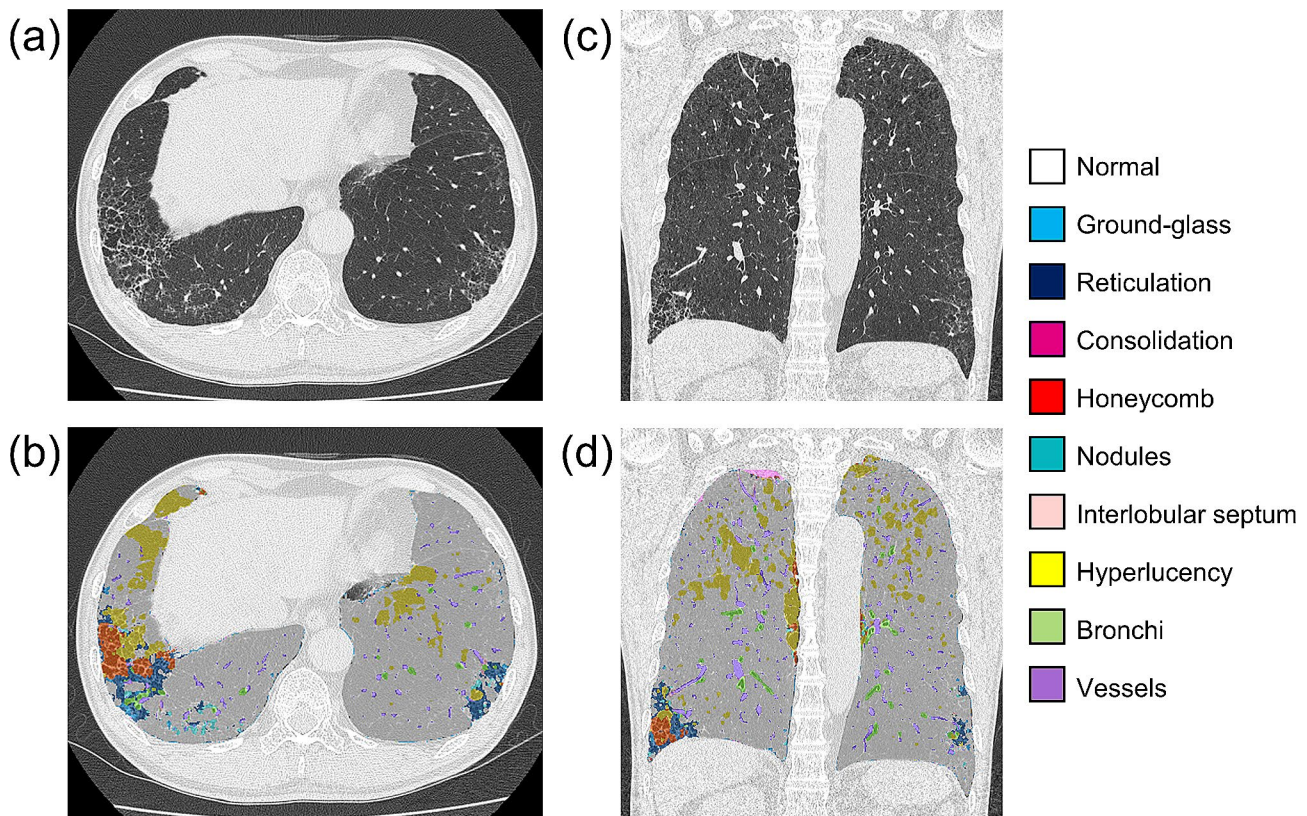
124 patients were included in the longitudinal analysis who took follow-up CT scans in 5 ± 1 years after the baseline scans (Fig. 1). Eight (7%) patients demonstrated new ILAs on the follow-up CT (mean CT scan interval = 4.9 ± 0.5 years) (Fig. S2). When comparing the baseline characteristics of patients consistently without ILAs and those with new ILAs (Table 3), pulmonary function and AIQCT indices were not different between the groups. Figure 3 shows the longitudinal changes in the AIQCT indices. The ILDvol and the volumes of its components (honeycombing, reticulations, and GGOs) increased in patients with new ILAs at the follow-up CT scan. The volumes of nodules also increased in patients with new ILAs at the follow-up, which may represent an increase in the number of nodules. The volume changes in these indices were greater in patients with new ILAs than in those consistently without ILAs after adjusting for age, sex, BMI, and smoking exposure (Table 4). Bronchial volume tended to increase in patients with new ILAs, although the difference did not reach statistical significance (Table 4). Representative images illustrating the ILAs monitored during the follow-up period are shown in Fig. 4.

When using the optimal ILDvol% threshold defined in the cross-sectional analysis (1.203%), 6 out of 8 patients were classified as having no ILAs at baseline, but all were classified as having ILAs at follow-up.

#### Discussion

This study showed that AI-based quantitative analysis identified COPD with ILAs with high sensitivity and specificity. Furthermore, ILAs appeared in 7% of patients





**Fig. 2** CT images of COPD with ILAs and corresponding AIQCT images

Legend: The axial CT image of a 68-year-old male patient with COPD and ILAs in the discovery cohort (Fig. 2. a) and the corresponding AIQCT image overlaid on the original image (Fig. 2. b). Sagittal image of the same patient (Fig. 2. c) and the corresponding AIQCT image (Fig. 2. d). The ILD volume was 150 mL (2.90%)

with COPD 5 years after baseline CT acquisition. The volumes of not only GGOs, reticulations, and honeycombing but also nodules increased in patients with new ILAs. This is the first study to classify the findings from chest CT scans into detailed lesions, including airway lesions and to quantitatively analyze and longitudinally assess patients with COPD and ILAs.

The prevalence of ILAs in patients with COPD in this study was 10 to 14%, which was consistent with the previous reports [20, 21]. ILAs in patients with COPD are more symptomatic, frequently exacerbated, and have a poor prognosis [8, 20, 22]. Therefore, the effort to detect ILAs in patients with COPD is crucial for understanding and managing disease progression. Quantitative interstitial features assessed by local histogram- and distance-based method are associated with pulmonary functions, respiratory symptoms, and mortality in patients with COPD [23]. The increase of quantitative interstitial features is associated with an annual decline in FVC, a decrease in exercise tolerance, and a poor mortality in longitudinal assessments [11]. Furthermore, the progression of interstitial changes quantified using deep learning-based method had further impact on mortality in addition to the progression of emphysema in the COPD

cohort [24]. This study extends those findings by providing a longitudinal, quantitative assessment of patients with new ILAs via a detailed classification of chest CT scans using AIQCT.

AIQCT achieved good diagnostic performance with high sensitivity and specificity in identifying ILAs. This result is comparable to that from previous reports, although the quantifying techniques differed [25–27]. The threshold values in this study (1.203%) and previous reports (1.8 to 3.6% [25–27]) are also lower than the threshold value for visual assessment proposed by the Fleischner Society (5%) [7]. The visual quantification of ILD volume based on tomographic images might be difficult, and the volume itself is usually overestimated [27]. In the sensitivity analysis, the diagnostic performance was not improved even when the lung volume was divided. This might be because ILD lesions are usually localized in the basal part of the lung in patients with ILAs, and artifacts on CT images did not affect the diagnosis of quantitative ILAs.

ILAs emerged in 7% of patients with COPD within 5 years in this study. The prevalence of new ILAs was higher than that in a population-based study [28]. This study included more at-risk patients, that is, older

**Table 3** Baseline characteristics of patients with COPD without ILAs at enrollment who subsequently developed ILAs and those who consistently showed no ILA findings on follow-up CT scans

	Consistently without ILA		new ILA		P value
n	103		8		
Follow-up duration, y	4.9	± 0.5	5.2	± 0.3	0.07
Age, y	69.1	± 7.6	74.98	± 8.2	0.04
Sex, male	94	(91.3)	8	(100)	0.842
BMI, kg/m <sup>2</sup>	21.8	± 2.7	23.8	± 1.5	0.035
Pack-years	64.5	± 34.9	50.4	± 23.8	0.266
Smoking status, past	74	(71.8)	6	(75)	1
mMRC, ≥ 2	27	(26.2)	2	(25)	1
FVC, L	3.23	± 0.77	3.09	± 0.69	0.601
% predicted	93.6	± 17.7	97.1	± 22.7	0.59
FEV <sub>1</sub> , L	1.57	± 0.62	1.56	± 0.52	0.981
% predicted	58.3	± 19.9	63.3	± 18.1	0.49
FEV <sub>1</sub> /FVC, %	47.9	± 12.9	50.2	± 9.1	0.625
D <sub>LCO</sub> , mL/min/mmHg	13.35	± 5.02	12.24	± 3.16	0.541
% predicted	60.5	± 20.7	61.2	± 18.8	0.929
Normal lungs, mL	4226	± 897	3966	± 929	0.432
ILD volume, mL	52.4	± 38.6	49.4	± 13.7	0.828
Ground-glass opacities, mL	45.1	± 35.7	38.4	± 9.7	0.596
Reticulations, mL	6.3	± 6.2	10.2	± 5.2	0.084
Consolidations, mL	7.6	± 3.7	8.1	± 2.3	0.704
Honeycombing, mL	1.0	± 1.7	0.86	± 1.3	0.802
Nodules, mL	5.7	± 4.6	6.6	± 4.4	0.575
Hyperlucencies, mL	808	± 994	599	± 674	0.561
Bronchi, mL	76.8	± 20.8	74.2	± 17.2	0.739
Vessels, mL	212.2	± 55.2	199.8	± 65.6	0.547

Data are the mean ± standard deviation or the number of patients with the percentage in parentheses. *ILA* interstitial lung abnormality; *BMI* body mass index; *mMRC* modified British Medical Research Council Dyspnea scale; *FVC* forced vital capacity; *FEV<sub>1</sub>*, forced expiratory volume in 1 s; *D<sub>LCO</sub>* diffusing capacity of the lung for carbon monoxide; *ILD* interstitial lung disease

patients and those with greater smoke exposure [29]. The baseline pulmonary function and volumes of CT regions did not differ between patients who developed ILAs and those who consistently remained without ILAs, which indicates that the occurrence of ILAs cannot be predicted by baseline pulmonary function or AIQCT indices.

The longitudinal changes in volumes of ILD regions and nodules were greater and that in bronchial volumes tended to be greater in patients with new ILAs than in those consistently without ILAs. Recently, some studies have shown that small airways are important to the pathogenesis of ILD or ILAs [30–33]. The microCT analysis of unbiased, systematic uniform random tissue samples from patients with IPF showed that the terminal bronchiole was dilated even in the presence of lesions without fibrosis [31]. The airway wall on HRCT is thicker in subjects with ILAs than in those without ILAs [30]. Furthermore, bronchiectasis and peribronchial fibrosis

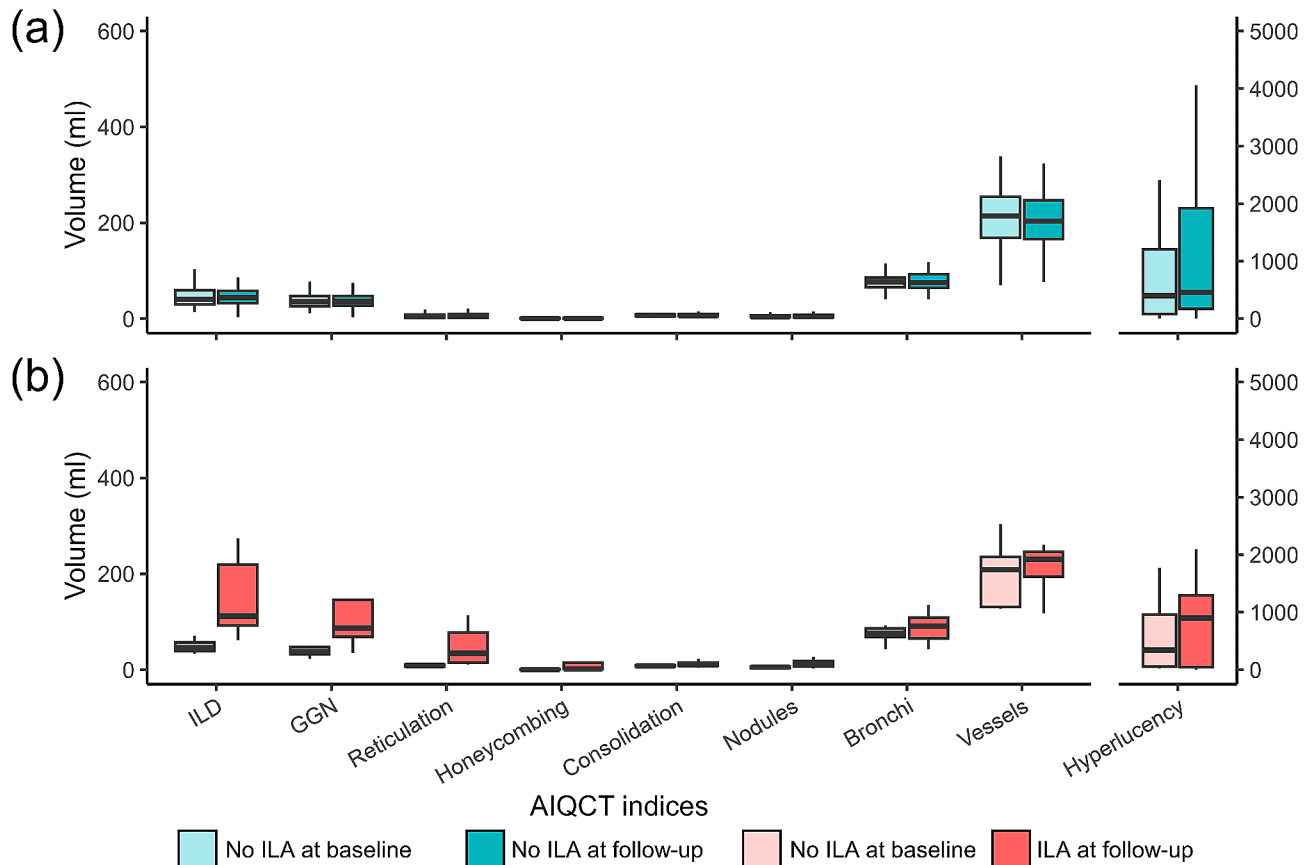
**Table 4** Longitudinal changes in AIQCT indices

	Consistently without ILAs	New ILAs	Adjusted difference	P value
n	103	8		
ILD volume, mL	-2.51 ± 33.45	204.20 ± 235.75	197.2 [145, 249.4]	< 0.001
%	-0.11 ± 0.96	4.64 ± 5.46	4.6 [3.3, 5.9]	< 0.001
Ground-glass opacity, mL	-5.31 ± 29.90	110.11 ± 163.87	111.9 [72.6, 151.2]	< 0.001
%	-0.17 ± 0.90	2.63 ± 4.30	2.8 [1.7, 3.8]	< 0.001
Reticulation, mL	1.91 ± 6.72	85.98 ± 160.76	78.6 [46.6, 110.5]	< 0.001
%	0.04 ± 0.15	1.83 ± 3.39	1.7 [1, 2.4]	< 0.001
Honeycombing, mL	0.89 ± 4.19	8.11 ± 12.77	6.7 [2.7, 10.7]	< 0.001
%	0.02 ± 0.08	0.18 ± 0.27	0.1 [0.1, 0.2]	< 0.001
Consolidation, mL	4.75 ± 30.81	5.17 ± 8.59	-0.2 [-23.4, 23]	0.99
%	0.08 ± 0.53	0.11 ± 0.18	0 [-0.4, 0.4]	0.90
Nodules, mL	0.29 ± 4.39	8.29 ± 13.62	8.2 [4.2, 12.3]	< 0.001
%	0.00 ± 0.12	0.17 ± 0.30	0.2 [0.1, 0.3]	< 0.001
Bronchi, mL	3.15 ± 14.79	15.00 ± 30.70	10.8 [-1.8, 23.3]	0.09
%	0.07 ± 0.32	0.32 ± 0.69	0.2 [-0.1, 0.5]	0.13
Vessels, mL	-7.26 ± 59.18	14.32 ± 87.75	27.1 [-19.8, 74]	0.25
%	-0.12 ± 1.17	0.38 ± 1.94	0.7 [-0.3, 1.6]	0.17
Hyperlucency, mL	253.80 ± 467.99	236.01 ± 394.52	162.1 [-167.6, 491.8]	0.33
%	4.95 ± 10.50	4.76 ± 7.89	3.8 [-3.5, 11.1]	0.30

Data are the mean ± standard deviation or adjusted mean differences with 95% confidence intervals in parentheses. The differences between patients who did not develop ILA and those who developed ILA were adjusted by age, sex, BMI, smoking status, and cumulative smoking exposure. *ILA* interstitial lung abnormality; *ILD* interstitial lung disease

were identified in ILA lungs in histopathological studies [32]. These airway changes may appear as nodules due to the resolution of HRCT. This study supports the hypothesis that interstitial fibrotic changes may start in the bronchial regions.

The interrater agreement was not high, neither between CT-experienced pulmonologists or with respect to a chest radiologist. Airspace enlargement with fibrosis, scar-like lesions, and paraseptal emphysema may make it harder to assess the existence of ILAs, especially in patients with COPD [34]. AIQCT is useful for providing objective and reproducible assessments of even slight interstitial abnormalities in emphysematous patients. Furthermore, it can detect the progression of ILAs. To elucidate the pathogenesis of ILAs and their clinical sequences to ILD, repeated histological analyses are



**Fig. 3** Longitudinal changes in AIQCT indices in patients consistently without ILAs and those with new ILAs.

Legend: Each AIQCT index is shown at baseline and at follow-up for patients consistently without ILAs (Fig. 3. a) and those with new ILAs (Fig. 3. b)

needed. However, biopsy is too invasive to repeat over time, and the biopsy procedure may alter the microenvironment of the lung. In contrast, CT image analysis is less invasive and allows repeated examinations without changing the lung microenvironment. Imaging studies using AIQCT may elucidate the pathogenesis of ILAs.

This study has some limitations. First, the number of new ILAs was small, making it difficult to explore factors associated with the future development of ILAs. Second, a substantial number of patients did not undergo follow-up CT scans within the period. A selection bias may exist when patients undergo follow-up CT scans. Third, most patients included in this study were male because COPD patients tend to be male in Japan and Asian countries [35, 36].

## Conclusions

In conclusion, this study showed that ILAs in patients with COPD could be measured using AIQCT. 7% of patients with COPD showed new ILAs at follow-up, and these patients could be identified by using AIQCT. Although additional studies in longitudinal cohorts are needed, AIQCT revealed that honeycombing,

reticulation, GGO, and nodule volumes were greater in patients who developed ILAs.

## Abbreviations

ILA	interstitial lung abnormality
COPD	chronic obstructive pulmonary disease
AI	artificial intelligence
ILD	interstitial lung disease
CPFE	combined pulmonary fibrosis and emphysema
HRCT	high-resolution computed tomography
AIQCT	Artificial intelligence based quantitative CT image analysis software
GGO	ground-glass opacity
IPF	idiopathic pulmonary fibrosis
FEV <sub>1</sub>	forced expiratory volume in 1 s
FVC	forced vital capacity

## Supplementary Information

The online version contains supplementary material available at <https://doi.org/10.1186/s12890-024-03002-z>.

Supplementary Material 1

## Author contributions

YS: Conceptualization, Data curation, Formal analysis, Investigation, Methodology, Visualization, Writing– original draft, NT: Conceptualization, Data curation, Methodology, Software, Supervision, Writing– review & editing, RS: Data curation, Software, Supervision, Writing– review & editing, TM:



Data curation, Writing– review & editing, SK: Methodology, Writing– review & editing, HS: Data curation, Software, Writing– review & editing, ST: Data curation, Writing– review & editing, K Terada: Data curation, Writing– review & editing, KI: Writing– review & editing, K Tanizawa: Software, Writing– review & editing, TO: Conceptualization, Methodology, Software, Writing– review & editing, T Handa: Methodology, Software, Writing– review & editing, SS: Conceptualization, Data curation, Methodology, Writing– review & editing, SM: Data curation, Writing– review & editing, T Hirai: Supervision, Writing– review & editing.

#### Funding

The data collection was supported by Japan Society for the Promotion of Science grants (16390234, 21590964, 25461156), and the analysis of the archived samples was supported by Japan Society for the Promotion of Science grant (19K08624 and 22K08233).

#### Data availability

All data generated or analyzed during this study are included in this article and its supplementary material files. Further enquiries can be directed to the corresponding author.

#### Declarations

##### Ethics approval and consent to participate

This study was conducted in accordance with the Declaration of Helsinki and approved by the ethics committee of Kyoto University Hospital (No. R1660-3 and No. C1311). Written informed consent was obtained from all patients in this study.

##### Consent for publication

Not applicable.

##### Competing interests

N.T., K.T., T.O., T.Handa and T.Hiari. were supported by grants from FUJIFILM Co., Ltd. And Daiichi Sankyo Company, Ltd. T. Handa is in the employment of the Collaborative Research Laboratory funded by Teijin Pharma Co., Ltd. S.S. received grants from FUJIFILM Co., Ltd., Nippon Boehringer Ingelheim, Philips-Respironics, Fukuda Denshi, Fukuda Lifetec Keiji, and ResMed. None of these companies had a role in the design or analysis of the study or in the writing of the manuscript. The other authors have no conflicts of interest to declare.

##### Author details

<sup>1</sup>Department of Respiratory Medicine, Graduate School of Medicine, Kyoto University, Kyoto, Japan

<sup>2</sup>Department of Diagnostic Imaging and Nuclear Medicine, Graduate School of Medicine, Kyoto University, Kyoto, Japan

<sup>3</sup>Institute of Mathematics for Industry, Kyusyu University, Fukuoka, Japan

<sup>4</sup>Respiratory Medicine and General Practice, Terada Clinic, Himeji, Hyogo, Japan

<sup>5</sup>Department of Respiratory Medicine, Kyoto City Hospital, Kyoto, Japan

<sup>6</sup>Department of Advanced Medicine for Respiratory Failure, Graduate School of Medicine, Kyoto University, Kyoto, Japan

<sup>7</sup>Department of Respiratory Care and Sleep Control Medicine, Graduate School of Medicine, Kyoto University, Kyoto, Japan

<sup>8</sup>Department of Respiratory Medicine, Nara Medical University, Kashihara, Nara, Japan

<sup>9</sup>Department of Respiratory Medicine, Graduate School of Medicine, Kyoto University, 54 Kawahara-cho, Shogoin, Sakyo-ku, 606-8507 Kyoto, Kyoto, Japan

Received: 18 December 2023 / Accepted: 9 April 2024

Published online: 23 April 2024

#### References

1. Global strategy for prevention, Diagnosis and Management of Copd (2024 report). 2024.
2. Beghé B, Cerri S, Fabbri LM, Marchioni A, COPD. Pulmonary fibrosis and ILAs in aging smokers: the Paradox of striking different responses to the major risk factors. *Int J Mol Sci.* 2021;22:9292.
3. Cottin V, Nunes H, Brillet PY, Delaval P, Devouassaoux G, Tillie-Leblond I, et al. Combined pulmonary fibrosis and emphysema: a distinct underrecognised entity. *Eur Respir J.* 2005;26:586–93.
4. Cottin V, Inoue Y, Selman M, Ryerson CJ, Wells AU, Agustí A, et al. Syndrome of Combined Pulmonary Fibrosis and Emphysema an Official ATS/ERS/JRS/ALAT Research Statement. *Am J Respir Crit Care Med.* 2022;206:E7–41.
5. Hage R, Gautschi F, Steinack C, Schuurmans MM, Gao W, Nishino M, et al. Association between interstitial lung abnormalities and all-cause mortality. *JAMA - J Am Med Association.* 2016;315:672–81.
6. Hoyer N, Wille MMW, Thomsen LH, Wilcke T, Dirksen A, Pedersen JH, et al. Interstitial lung abnormalities are associated with increased mortality in smokers. *Respir Med.* 2018;136:77–82.
7. Suman G, Koo CW. Recent advancements in computed Tomography Assessment of Fibrotic interstitial lung diseases. *J Thorac Imaging.* 2023. <https://doi.org/10.1097/RTI.0000000000000705>.
8. Choi B, Adan N, Doyle TJ, San José Estépar R, Harmouche R, Humphries SM, et al. Quantitative interstitial abnormality progression and outcomes in the Genetic Epidemiology of COPD and Pittsburgh Lung Screening Study cohorts. *Chest.* 2023;163:164–75.
9. Maldonado F, Moua T, Rajagopalan S, Karwoski RA, Raghunath S, Decker PA, et al. Automated quantification of radiological patterns predicts survival in idiopathic pulmonary fibrosis. *Eur Respir J.* 2014;43:204–12.
10. Aoki R, Iwasawa T, Saka T, Yamashiro T, Utsunomiya D, Misumi T et al. Effects of Automatic Deep-Learning-based lung analysis on quantification of interstitial lung disease: correlation with pulmonary function test results and prognosis. *Diagnostics.* 2022;12.
11. Handa T, Tanizawa K, Oguma T, Uozumi R, Watanabe K, Tanabe N, et al. Novel Artificial Intelligence-based technology for chest computed Tomography Analysis of Idiopathic Pulmonary Fibrosis. *Ann Am Thorac Soc.* 2021. <https://doi.org/10.1513/AnnalsATS.202101-044OC>.
12. Terada K, Muro S, Sato S, Ohara T, Haruna A, Marumo S, et al. Impact of gastro-oesophageal reflux disease symptoms on COPD exacerbation. *Thorax.* 2008;63:951–5.
13. Tanabe N, Muro S, Hirai T, Oguma T, Terada K, Marumo S, et al. Impact of exacerbations on emphysema progression in chronic obstructive pulmonary disease. *Am J Respir Crit Care Med.* 2011;183:1653–9.
14. Tanimura K, Sato S, Fuseya Y, Hasegawa K, Uemasu K, Sato A, et al. Quantitative assessment of erector spinae muscles in patients with chronic obstructive pulmonary disease novel chest computed tomography-derived index for prognosis. *Ann Am Thorac Soc.* 2016;13:334–41.
15. Tanabe N, Shimizu K, Terada K, Sato S, Suzuki M, Shima H, et al. Central airway and peripheral lung structures in airway disease-dominant COPD. *ERJ Open Res.* 2021;7:00672–2020.
16. McHugh ML. Interrater reliability: the kappa statistic. *Biochem Med (Zagreb).* 2012;22:276.
17. Hata A, Schiebler ML, Lynch DA, Hatabu H. Interstitial lung abnormalities: state of the art. *Radiology.* 2021;301:19–34.
18. Liu Y. Impact of interstitial lung abnormalities on Disease expression and outcomes in COPD or Emphysema. A systematic review. *February;* 2023.
19. Ash SY, Harmouche R, Ross JC, Diaz AA, Rahaghi FN, Sanchez-Ferrero GV, et al. Interstitial features at chest CT enhance the deleterious effects of emphysema in the COPDGene cohort. *Radiology.* 2018;288:600–9.
20. Ash SY, Harmouche R, Putman RK, Ross JC, Diaz AA, Hunninghake GM, et al. Clinical and Genetic associations of objectively identified interstitial changes in smokers. *Chest.* 2017;152:780–91.
21. Ash SY, Choi B, Oh A, Lynch DA, Humphries SM. Deep Learning Assessment of Progression of Emphysema and Fibrotic interstitial lung abnormality. *Am J Respir Crit Care Med.* 2023;208:666–75.
22. Kim MS, Choe J, Hwang HJ, Lee SM, Yun J, Kim N et al. Interstitial lung abnormalities (ILA) on routine chest CT: comparison of radiologists' visual evaluation and automated quantification. *Eur J Radiol.* 2022;157.
23. Mathai SK, Humphries S, Kropski JA, Blackwell TS, Powers J, Walts AD, et al. MUC5B variant is associated with visually and quantitatively detected preclinical pulmonary fibrosis. *Thorax.* 2019;74:1131–9.



27. Chae KJ, Lim S, Seo JB, Hwang HJ, Choi H, Lynch D, et al. Interstitial lung abnormalities at CT in the Korean National Lung Cancer Screening Program: prevalence and deep learning-based texture analysis. *Radiology*. 2023. <https://doi.org/10.1148/radiol.222828>.
28. McGroder CF, Hansen S, Hinckley Stukovsky K, Zhang D, Nath PH, Salvatore MM, et al. Incidence of interstitial lung abnormalities: the MESA Lung Study. *Eur Respir J*. 2023;61:2201950.
29. Bozzetti F, Paladini I, Rabaiotti E, Franceschini A, Alfieri V, Chetta A, et al. Are interstitial lung abnormalities associated with COPD? A nested case-control study. *Int J Chron Obstruct Pulmon Dis*. 2016;11:1087–96.
30. Miller ER, Putman RK, Diaz AA, Xu H, Estepar RSJ, Araki T, et al. Increased airway wall thickness in interstitial lung abnormalities and idiopathic pulmonary fibrosis. *Ann Am Thorac Soc*. 2019;16:447–54.
31. Ikezoe K, Hackett TL, Peterson S, Prins D, Hague CJ, Murphy D, et al. Small airway reduction and fibrosis is an early pathologic feature of idiopathic pulmonary fibrosis. *Am J Respir Crit Care Med*. 2021;204:1048–59.
32. Verleden SE, Vanstapel A, Jacob J, Goos T, Hendriks J, Ceulemans LJ, et al. Radiologic and Histologic Correlates of Early Interstitial Lung Changes in explanted lungs. *Radiology*. 2022. <https://doi.org/10.1148/radiol.221145>.
33. Verleden SE, Tanabe N, McDonough JE, Vasilescu DM, Xu F, Wuys WA, et al. Small airways pathology in idiopathic pulmonary fibrosis: a retrospective cohort study. *Lancet Respir Med*. 2020;8:573–84.
34. Watadani T, Sakai F, Johkoh T, Noma S, Akira M, Fujimoto K, et al. Interobserver Variability in the CT Assessment of Honeycombing in the lungs. *Radiology*. 2013;266:936–44.
35. Takahashi S, Betsuyaku T. The chronic obstructive pulmonary disease comorbidity spectrum in Japan differs from that in western countries. *Respiratory Invest*. 2015;53:259–70.
36. Lee TS, Jin KN, Lee HW, Yoon SY, Park TY, Heo EY, et al. Interstitial Lung Abnormalities and the clinical course in patients with COPD. *Chest*. 2021;159:128–37.

### Publisher's Note

Springer Nature remains neutral with regard to jurisdictional claims in published maps and institutional affiliations.